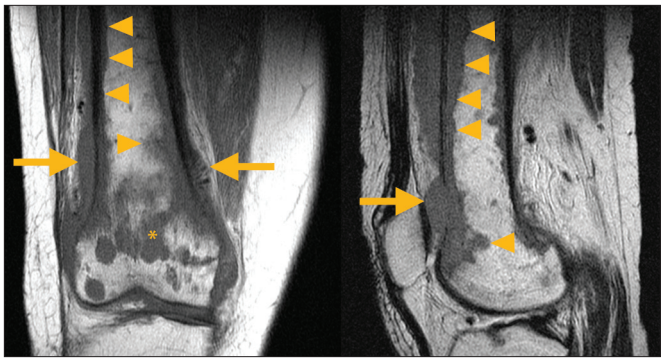

FIGURE 2. (ABOVE) T1-weighted magnetic resonance imaging of the right knee (left, coronal view; right, sagittal view) demonstrating multiple T1 hypointense lesions of the distal femur (asterisk), concerning for metastatic disease and extensive cortical change of the distal femur (arrowheads), with cortical and periosteal proliferation (arrows) consistent with hypertrophic osteoarthropathy.

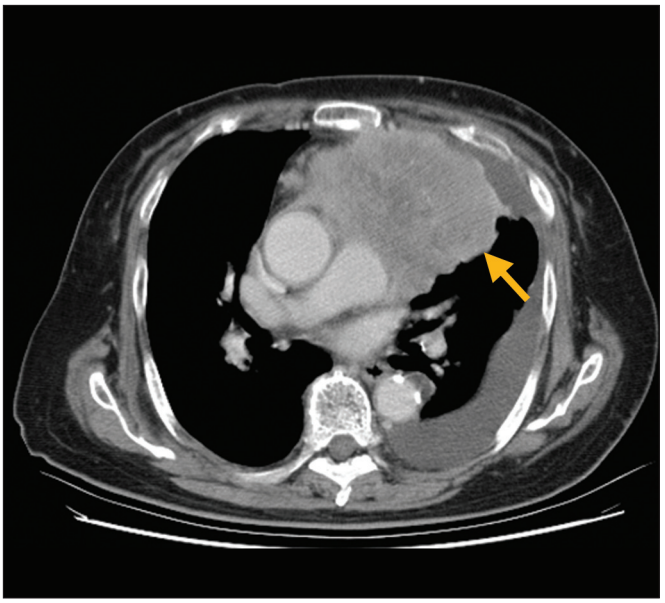

FIGURE 4. (RIGHT) Computed tomography of the chest (axial view) demonstrating a soft tissue mass (arrow) of the left lung, which measured 11 × 9 × 7 cm, with invasion of the mediastinum and pleura with associated pleural effusion.

Painful Hypertrophic Osteoarthropathy and Metastatic Bone Lesions as the Initial Presentation of Lung Cancer

MAN-HSIN HUNG, MD, *Division of Haematology & Oncology, Department of Medicine, Taipei Veterans General Hospital and National Yang-Ming University School of Medicine, Taipei, Taiwan.*
KUAN-TING HOU, MD, *Department of Medicine, Taipei Veterans General Hospital and National Yang-Ming University School of Medicine, Taipei, Taiwan.*
CHUN-YU LIU, MD, *Division of Haematology & Oncology, Department of Medicine, Taipei Veterans General Hospital and National Yang-Ming University School of Medicine, Taipei, Taiwan.*

The patient was a 67-year-old woman, who was evaluated by her primary care physician for progressively worsening right knee pain, described as constant in nature and as having been present for the past week. The patient's symptoms were insidious in onset, not associated with a traumatic event, and interfered with activities of daily living and sleeping. The patient did not exhibit constitutional symptoms and had an unremarkable past medical and surgical history. Physical examination demonstrated an antalgic gait and limited right knee range of motion with no apparent joint effusion.

Given the progressively worsening nature of the patient's right knee pain in the absence of trauma, knee radiographs were ordered, which revealed a periosteal reaction with subtle lucent lesions of the right distal femur (**FIGURE 1,** available at www.jospt.org), which were concerning for sinister pathology. Subsequent magnetic resonance imaging revealed multiple variable-sized T1 hypointense lesions of the distal femur with cortical and periosteal proliferation (**FIGURE 2**), suggestive of metastatic bone lesions and hypertrophic osteoarthropathy, respectively.

These findings warranted further evaluation with dedicated chest imaging. Chest radiography (**FIGURE 3,** available at www.jospt.org) revealed a mass silhouetting the left cardiomediastinal border and deviating the trachea toward the right side, which was further delineated by computed tomography (**FIGURE 4**). After further medical evaluation, the patient was diagnosed with non–small cell lung cancer with metastases of the mediastinum and right femur. The patient subsequently underwent right total knee arthroplasty, and chemotherapy and radiotherapy were administered for disease control. ◉ *J Orthop Sports Phys Ther 2012;42(7):659. doi:10.2519/jospt.2012.0413*